

Improved bone healing after oral application of specific bioactive collagen peptides

Hans-Christoph Knefeli¹, Michael Mueller-Autz²

Correspondence to: Hans-Christoph Knefeli - hans-christoph.knefeli@gelita.com

ABSTRACT

The complete and undisturbed healing of bone fractures is a key priority for surgeons and patients, so intensive efforts are made to improve bone healing with a variety of approaches. Oral therapies with collagen peptides are a relatively new therapeutic approach.

In this observational study, the impact of collagen peptides on bone healing was investigated in a group of 28 (14 verum/14 placebo) patients of both genders with different fracture locations. Some patients underwent surgery, while others were treated conservatively. The patients who received bioactive collagen peptide treatment (FORTIBONE®) had a clearly better outcome regarding bone healing than the placebo group, half of whom showed suboptimal or bad results. No side effects or intolerance to the product were reported.

The results of this investigation confirm the positive impact of collagen peptides on bone healing. The data suggest that FORTIBONE® can be used to improve fracture healing, even in cases where a normal outcome is expected, and to achieve faster healing.

Keywords

Bioactive collagen peptides
Nutritional supplement
Bone fracture
Bone healing

Introduction

Complete and undisturbed bone healing in a timely fashion is a key priority for surgeons and patients. However, a deterioration in recovery is sometimes observed in cases where bone healing is initially normal, which often results from the patient's individual circumstances. Comorbidities such as diabetes or vascular diseases often result in prolonged or insufficient bone healing.

One common method for treating fractures is immobilization of the affected bone, often with braces or splints that include adjacent joints. Additional therapies for disturbed bone healing have also emerged in recent years, although their benefits are still controversial. Oral therapies to support bone healing are a fairly new therapeutic approach.

Numerous experimental studies have been performed to assess the impact of bioactive collagen peptides (BCP) on the metabolic and degenerative processes involved in bone formation and mineralization [1–3]. Their bioavailability

has also been examined in a validated model that showed collagen peptides accumulate in the target tissue [4, 5]. Experimental studies on primary human osteoblasts have demonstrated the stimulatory effect of BCP on the biosynthesis of bone extracellular matrix (ECM) macromolecules. Proteoglycans in the ECM are involved in the regular formation of the inorganic hydroxyapatite crystals and thus support bone mineral density [6, 7].

The significant decrease in re-fracture rates after collagen peptide ingestion, as observed in clinical studies on osteoporotic patients [8, 9], was explained by the increased synthesis of organic bone matrix and the subsequent promotion of bone mineralization. In addition, bone matrix degradation decreased under BCP treatment.

To date, clinical evidence on the efficacy of specific orally administered collagen peptides on bone healing after fractures has not been available. Their effect on the healing of bone fractures was therefore investigated in the current study on patients undergoing operative or conservative treatment.

Material and methods

FORTIBONE® (GELITA AG, Germany) is a special orally administered collagen product optimized for bone health,

¹GELITA AG, D-69412 Eberbach, Germany

²Mueller-Autz & Partners Surgical Practice, Heidelberg, Germany

which contains specific collagen peptides with an average molecular weight of 5.0 kDa. It has been certified as GRAS (Generally Recognized As Safe) by the FDA.

In the trial, 28 patients were randomly assigned to a verum (14 patients) or placebo (14 patients) group. Participants in both groups received 30 to 90 daily doses of 10 g FORTIBONE® or a placebo (maltodextrin 10 g) over the observation period. All patients provided informed consent for the study.

The verum group consisted of 12 female patients aged 17–87 years, and two male patients aged 24 and 76. All had fractures of the upper (2 finger, 4 radius, 1 humerus) or lower extremities (4 metatarsal, 2 fibula), or of the coccyx (1). The patients received conservative (11) or surgical treatment (3) (Table 1). The placebo group comprised eight female patients aged 59–93, and six male patients aged 16–82. All had fractures of the upper (1 metacarpal, 1 finger, 3 radius) or lower extremities (5 metatarsal, 3 fibula, 1 ankle), or of the coccyx (1). The patients received conservative (12) or surgical treatment (2) (Table 2).

Intake of the daily dose of verum or placebo began on the day of the patient’s first visit to their treating physician. X-rays were taken before the first oral intake, during the healing phase, and at the end of treatment (Figs. 1–4).

The X-rays and clinical outcomes were evaluated by four experienced physicians who were blinded to the treatment (verum or placebo). The result was assessed as very good, good, suboptimal or bad for the following criteria:

- Consolidation of the fracture/onset of fusion
- Fracture still traceable after normal healing time
- Demineralization or atrophic inactivity
- Pseudarthrosis
- Cloudy healed fracture or healed with the correct shape

No.	Gender	Year of birth	Diagnosis	Remarks	Rating
1	F	1999	Distal fibula fracture	Conservative	1
2	F	1957	Weber A fracture	Conservative	4
3	F	1945	Distal radius fracture incl. joint	Conservative	1
4	F	1964	3rd grade compound finger fracture	Operative	1
5	F	1930	5th Metatarsal fracture	Conservative	2
6	F	1980	Distal radius fracture	Operative	1
7	F	1976	Proximal humerus fracture	Operative/pseudarthrosis	2
8	M	1940	5th Metatarsal fracture	Conservative	1
9	F	1935	Proc.styl. radius fracture	Conservative	2
10	F	1953	Coccyx fracture	Conservative	4
11	M	1993	(Multiple fragment) 5th Metatarsal basic fracture	Conservative	3
12	F	1980	5th Finger basic fracture (proximal phalanx)	Conservative	1
13	F	1935	(Multiple fragment) 4th and 5th Metatarsals fracture	Conservative	2
14	F	1942	Distal radius fracture	Conservative	2

Table 1 - Diagnosis and evaluation of healing in 14 patients administered bioactive collagen peptides

No.	Gender	Year of birth	Diagnosis	Remarks	Rating
1	F	1933	5th Metatarsale fracture	Conservative/inactivity atrophy	4
2	F	1957	Weber B fracture	Conservative	3
3	F	1945	Weber B fracture	Conservative	4
4	F	1964	5th Metatarsale basic fracture	Conservative	2
5	F	1930	5th Metacarpale fracture	Conservative	2
6	F	1980	5th Metatarsale basic fracture	Conservative	4
7	F	1976	Bimalleolar ankle joint fracture	Conservative	3
8	M	1940	5th Metatarsal fracture	Conservative	3
9	F	1935	Distal radius fracture	Operative	2
10	F	1953	Distal radius fracture	Conservative	2
11	M	1993	Coccyx fracture	Conservative	4
12	F	1980	Distal radius fracture	Operative	1
13	F	1935	Finger fracture	Conservative	1
14	F	1942	Distal fibula fracture	Conservative	1

Table 2 - Diagnosis and evaluation of healing in 14 placebo patients

- Shortened, normal or slowed healing process
- Signs of inflammation (redness, hyperthermia)
- Pain, haematoma or neurological problems
- Skin condition after surgery (waviness, roughness, rosy or pale skin colour, elasticity and moisture)
- Additional curative therapy required such as iontophoresis.

Results

All study participants complied with the physicians’ instructions given at the first visit. No patient reported any side effects or intolerance to the collagen product.

The study revealed that six (43%) of the 14 patients in the verum group evaluated by the physicians had very good results, while a further five (36%) had good results. The patients themselves were highly satisfied with the healing of

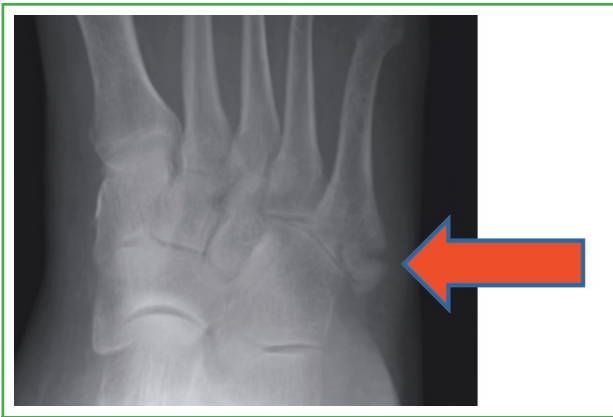

Figure 1 - Fracture directly after an accident in a patient in the placebo group

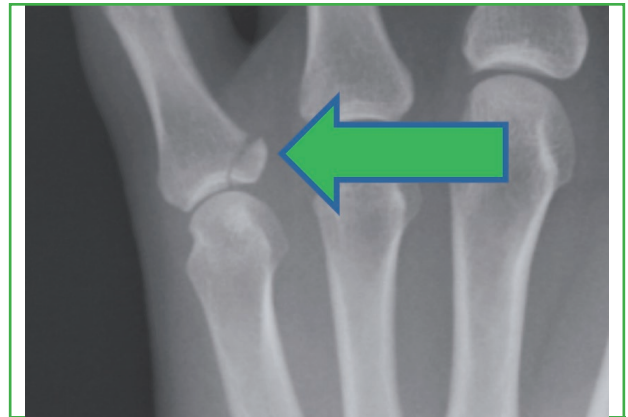


Figure 3 - Fracture directly after an accident in a patient in the verum group

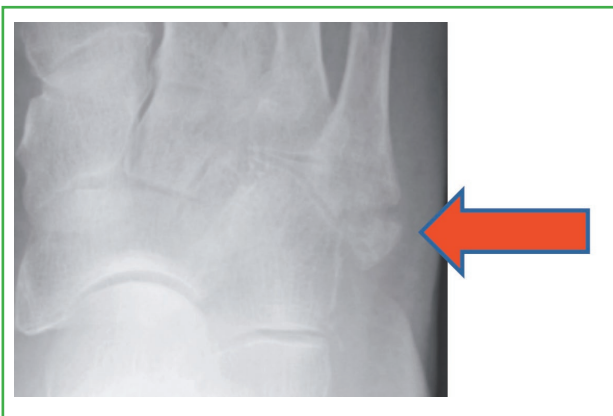


Figure 2 - The fracture practically unchanged after 6 weeks in the same patient as in Fig. 1

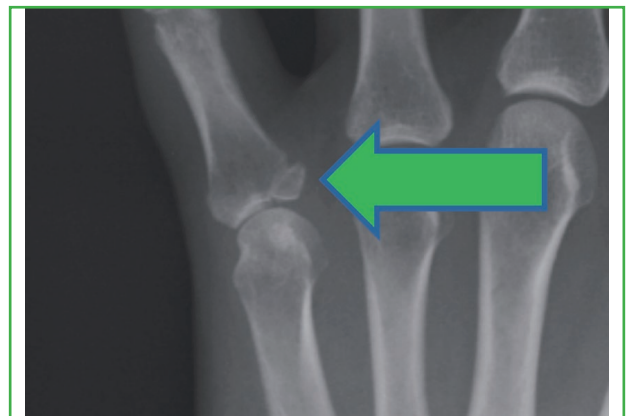


Figure 4 - Consolidated fracture after 6 weeks in the same patient as in Fig. 3

their bone. One (7%) patient had an ‘adequate’ outcome due to neurological problems, and two (14%) were assessed as having badly healed bones since their fractures did not mend in the correct shape. Overall, 79% of the patients in the verum group had either a good or a very good outcome (Fig. 5).

This contrasts sharply with the placebo group, where only three (21%) of the 14 patients were assessed as having a very good outcome. In addition, four (29%) patients had good results, while three (21%) had a suboptimal outcome (one

due to a prolonged consolidation period, one due to bone demineralization, and one due to Sudeck dystrophy) and four (29%) had badly healed bones. These findings show that 50% of the patients in the placebo group had a bad or suboptimal healing outcome (Fig. 6).

On balance, the patients treated with BCP clearly showed better bone healing than those who received the placebo (Figs. 5 and 6).

In addition, it appears that bone healing was accelerated with BCP supplementation, particularly in the elderly pa-

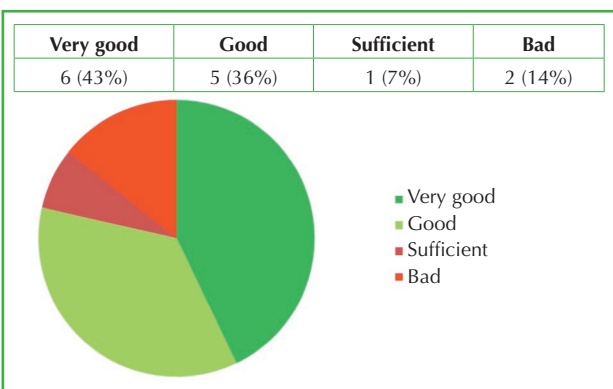


Figure 5 - Results in 14 patients taking verum (10 g FORTIBONE®)

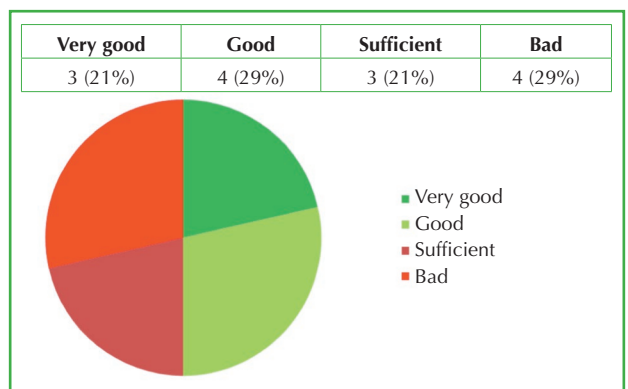


Figure 6 - Results in 14 patients taking placebo (10 g maltodextrin)

tients as evaluated by the attending physicians. It was also reported that spontaneous osteogenesis started earlier in complicated fractures when BCP was administered. One patient in the BCP group experienced an extremely shortened healing process, which was reduced from the usual 6 to only 4 weeks.

Discussion

The results of this observational trial demonstrated positive effects on bone healing after the oral application of BCP.

In the placebo group, 50% of the patients had a suboptimal or bad outcome, whereas only 21% of the patients in the verum group showed a suboptimal or bad result. In the treatment group, 79% had a very good or a good outcome.

Elderly patients in particular seem to experience major benefits from the oral intake of BCP. Even complicated fractures showed earlier osteogenesis after BCP was administered, irrespective of the patient's age.

The pronounced impact of BCP on connective tissue has been demonstrated in several clinical studies. The positive effects on healing of BCP treatment are probably attributable to increased bone metabolism due to a direct impact on extracellular matrix turnover, as well as an additional effect on bone mineralization [10, 11]. Shortened healing periods with improved angiogenesis have been observed in animal experiments [12, 13]. Other studies on humans also confirmed stimulation of granulation tissue and proteases, a decrease in inflammation parameters, and improved perfusion, especially with regard to microcirculation, after BCP administration [14, 15]. These findings might explain the beneficial results on bone healing observed after BCP treatment.

Conclusion

In summary, these findings show for the first time that BCP have a positive impact on bone healing. The data suggest an improved clinical outcome independent of the type of fracture. It must, however, be noted that these results apply only for the product used in this study, as other collagen hydrolysates or collagen peptides may show different effects. Future studies on a larger population should corroborate these positive results and attempt to elucidate the mode of action.

REFERENCES

1. Watanabe-Kamiyama M, Shimizu M, Kamiyama S, Taguchi Y, Sone H, Morimatsu F, Shirakawa H, Furukawa Y, Komai M (2010) Absorption and effectiveness of orally administered low molecular weight collagen hydrolysate in rats. *J Agric Food Chem* 58:835–841
2. König D, Oesser S, Scharla S, Zdzieblik D, Gollhofer A (2018) Specific collagen peptides improve bone mineral density and bone markers in postmenopausal women – a randomized controlled study. *Nutrients* 10(1). doi:10.3390/nu10010097
3. Daneault A, Prawitt J, Fabien Soulé V, Coxam V, Wittrant Y (2017) Biological effect of hydrolyzed collagen on bone metabolism. *Crit Rev Food Sci Nutr* 57(9):1922–1937
4. Shigemura Y, Kubomura D, Sato Y, Sato K (2014) Dose-dependent changes in the levels of free and peptide forms of hydroxyproline in human plasma after collagen hydrolysate ingestion. *Food Chem* 159:328–332
5. Osawa Y, Mizushige T, Jinno S, Sugihara F, Inoue N, Tanaka H, Kabuyama Y (2018) Absorption and metabolism of orally administered collagen hydrolysates evaluated by the vascularly perfused rat intestine and liver in situ. *Biomed Res (Tokyo)* 39(1):1–11
6. Amizuka N (2004) Bone quality in the respect of bone matrix. *Clin Calcium* 14:589–593
7. Kniep R (2002) Knochenarbeit mit kristallen und molekülen. *Max Planck Forschung* 04:39–42
8. Adam M, Spacek P, Hulejova H (2002) What is the effect of collagen peptides peroral administration in postmenopausal osteoporosis? *Ces Reumatol* 10:131–137
9. Adam M, Spacek P, Hulejova H, Galianova A, Blahos J (1998) May Collagen Hydrolysate Rich Diet (CHRD) extend the effect of calcitonin in postmenopausal osteoporosis? *Connect Tiss Dis* 17:25–36
10. Bradley EW, Oursler MJ (2008) Osteoclast culture and resorption assays. *Methods Mol Biol* 455:19–35
11. Nojiri H, Saita Y, Morikawa D, Kobayashi K, Tsuda C, Miyazaki T, Saito M, Marumo K, Yonezawa I, Kaneko K, Shirasawa T, Shimizu T (2011) Cytoplasmic superoxide causes bone fragility owing to low-turnover osteoporosis and impaired collagen cross-linking. *J Bone Miner Res* 26:2682–2694
12. Dang QF, Liu H, Yan JQ, Liu CS, Liu Y, Li J *et al* (2015) Characterization of collagen from haddock skin and wound healing properties of its hydrolysates. *Biomed Mater* 10(1):015022
13. Zhang Z, Zhao M, Wang J, Ding Y, Dai X, Li Y (2011) Oral administration of skin gelatin isolated from Chum salmon (*Oncorhynchus keta*) enhances wound healing in diabetic rats. *Mar Drugs* 9(5):696–711
14. Nonaka I, Katsuda S, Ohmon T *et al* (1997) In vitro and in vivo antiplatelet effects of enzymatic hydrolysates of collagen and collagen-related peptides. *Biosci Biotechnol Biochem* 61:772–775
15. Kouguchi T, Ohmon T, Shimizu M, Takahata Y, Maeyama Y, Suzuki T, Morimatsu F, Tanabe S (2013) Effects of a chicken collagen hydrolysate on the circulation system in subjects with mild hypertension or high-normal blood pressure. *Biosci Biotechnol Biochem* 77:691–696